

A Review of Tibial Tuberosity Advancement

By Jeff Mayo, DVM
For Veterinary Practice News

Probably the most common cause of lameness in the hind limb of the canine is cranial cruciate ligament (RCCL) rupture.

Many different procedures have been proposed with varying degrees of success to stabilize the knee, although most lack sound evidence-based medicine to substantiate their usefulness in veterinary medicine.

Currently, most will agree that tibial plateau leveling osteotomy¹ is the gold standard method of repair.

Based on stifle kinematics proposed by Nissell² and Tepic³, tibial tuberosity advancement, or TTA, was presented in 2002⁴ as a viable surgical method for treating RCCL in dogs. Since its clinical release, I have performed more than 800 cases, and taught more than 150 veterinarians how to perform the procedure.

The proposed stifle kinematics that supports TTA suggests that there is a joint force ap-

proximately parallel to the patellar tendon.

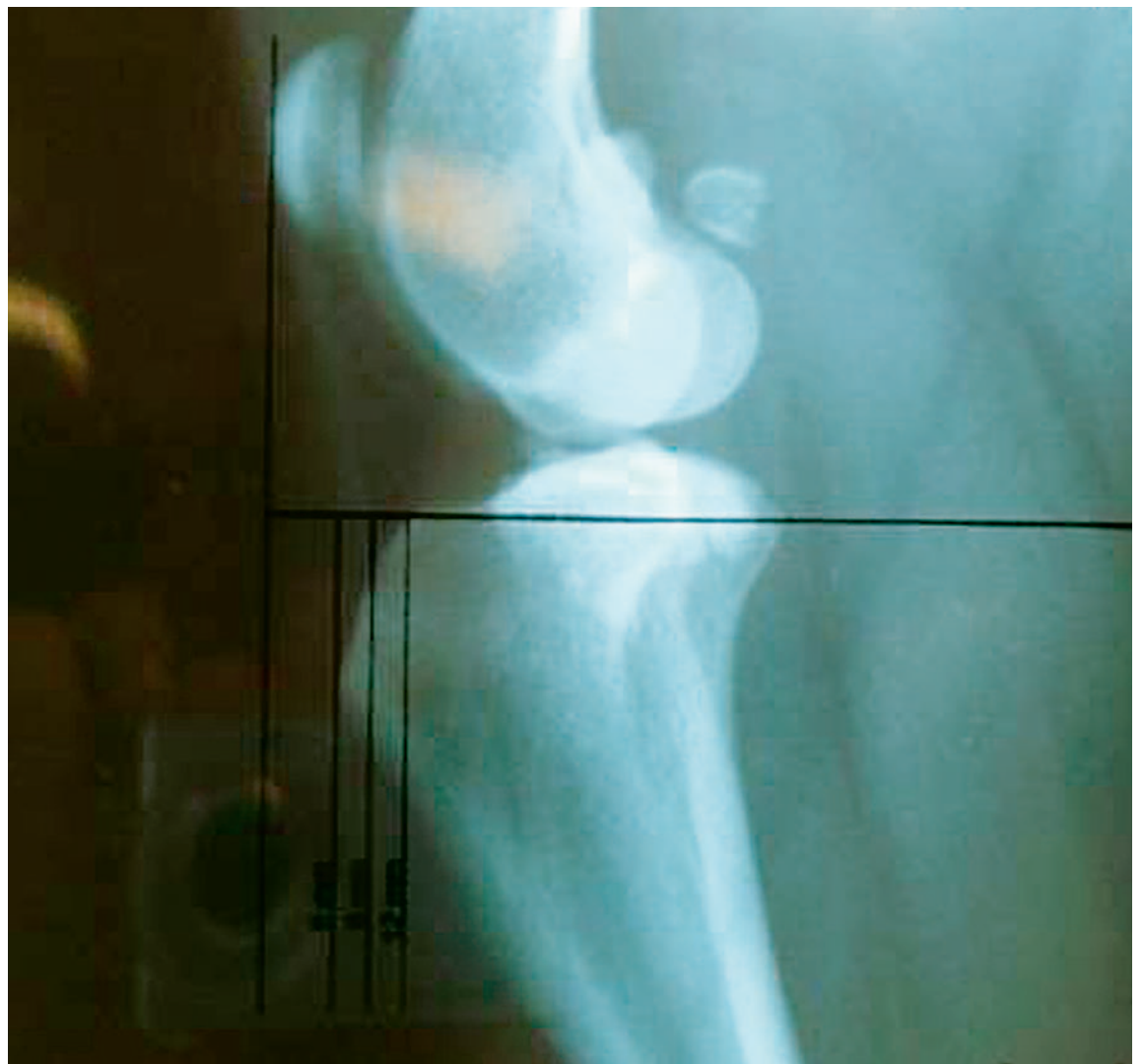As the knee progresses past 90 degrees of flexion into extension, there is a net cranial shear force, and when the knee flexes to less than 90 degrees there is a net caudal shear force in the stifle joint.

In the intact knee (no RCCL) these forces are countered by the cruciate ligaments. At exactly 90 degrees of flexion (or extension) the sum of these forces is neutral, a cross-over point, at which the patellar tendon should be 90 degrees to the tibial plateau.

Thus, the theory behind TTA is to advance the patellar tendon through a frontal plane sagittal osteotomy of the tibial tubercle and stabilize it with a commercially available advancement cage and tension band plate of pre-determined sizes.

Equipment requirements include:

- * Standard surgical pack suitable for orthopedics,
- * A power sagittal saw and drill, and



COURTESY OF DR. MAYO

* **Two of every size of implant available** (six sizes of plates and 12 sizes of cages are available).

Commercially available implants can stabilize stifles in patient sizes from 10 pounds and greater. These implants are available in steel or titanium. Screw sizes should include 2.4 mm in 10mm to 40 mm lengths, 2.7 mm in 18 mm to 24 mm lengths, and 3.5 mm in 18 mm to 26 mm lengths.

It is recommended that surgeons have on hand at least

tibia in a fashion similar to the TPLO, but with considerably less dissection of local tissues. The medial meniscus, an area of great debate, should be dealt with appropriately through a partial or complete meniscectomy if torn, or a releasing procedure if intact.

Appropriate assessment of the menisci include arthroscopic viewing or through a complete arthrotomy of the joint.

The craniomedial tibial crest and proximal tibial shaft are exposed through an incision in the

is planned in the frontal plane cranial to the long digital extensor groove. The distal extent should exit the tibial tubercle proximal to the first hole of the distal tension band plate.

The tension band plate should be attached prior to completion of the osteotomy. An appropriate-sized advancement cage is now inserted into the proximal aspect of the osteotomy with the assistance of a T-handle. The construct can now be reduced and checked for:

1. Proper positioning of the cage being at or slightly below the joint surface;
2. Slight proximal subluxation of the tibial tubercle to avoid iatrogenic patellar luxation;
3. Adequate and complete unhindered range of motion of the stifle joint; and
4. Neutralization of cranial tibial thrust.

Appropriate size screws may now be inserted to secure the implants.

Before closure, the osteotomy should be adequately flushed and filled with an appropriate allograft. The pes anserinus is closed in a simple continuous fashion with polydioxanone suture material. All remaining layers are closed in a routine fashion.

Radiographs are repeated to confirm proper implant placement. Postoperatively, patients are to remain on strict leash confinement, although appropri-

Complication rates have been very low, with the majority being easily dealt with.

two of every size screw recommended before performing the procedure.

Preoperative assessment of the stifle joint in preparation for surgery involves taking medial to lateral and craniocaudal views in a standing angle.

After assessment for concurrent skeletal problems, appropriate measurements are made for advancement cage and tension band plate size. Canine stifles with tibial plateau angles in excess of 30 degrees, or those with an obvious angular limb deformity, are deferred for the TPLO procedure.

TTA starts with a medial ap-


proach to the stifle and proximal pes anserinus tendon. This incision should start proximally along a line that parallels or is slightly cranial to the planned osteotomy. This incision should end on the medial tibial surface proximal to the medial saphenous vein. At the proximal extent of the tibial tuberosity, this tendon should be elevated to the cranial most extent and caudally to the medial collateral ligament.

The TTA jig is placed on the medial surface of the tibial proximal to the tibial tuberosity and secured.

A sufficient number of 2.0-mm holes are drilled to accommodate the appropriate tension band plate. Next, a sagittal osteotomy

Experience the Evolution..
Digital Doppler Ultrasound for the Veterinarian

TelaVet 500-D Color Doppler
starting from \$14,900



Linear, convex & microconvex probes
Digital image capture & storage
Color CFM and PW Doppler
Easy to learn and operate
2-10 MHz frequencies

19900 Mona Rd, #105 Tequesta, FL 33469
(800) 722-6838 • (561) 746-9527
www.classicmedical.com

Classic Medical
Since 1985
Classic Digital
IMAGING

Notebook Ultrasound

ate rehabilitation therapy may be sought under strict doctor guidance.

Patients return in two weeks for suture removal and re-evaluation, then again in eight weeks for follow up radiographs.

I have found clinical results to be exceedingly good. Most patients have gained maximum return to function in about 12 weeks with appropriate postoperative care and rehabilitation.^{5,6,7}

Complication rates have been very low, with the majority being easily dealt with.

Anecdotal clinical follow ups with this practitioner at two years on a number of cases have shown minimal arthritis involving operated joints. The procedure is exceedingly simple compared to TPLO, and is gaining popularity among many practitioners and surgeons throughout the U.S. ●

Jeff Mayo, DVM, Dipl. AVBP, owns Mayo Veterinary Services in Mountlake Terrace, Wash. He travels regularly, consulting and teaching veterinarians TTA, TPLO, THR and rigid endoscopy.

REFERENCE

1. Slocum B, Slocum TD: Tibial plateau leveling osteotomy for cranial cruciate ligament, in Bojrab MJ (ed): Current Techniques in Small Animal Surgery (ed 4). Baltimore, MD, Williams & Wilkins, 1998, pp 1209-1121

2. Nisell R, Ne´meth G, Ohlse´n H: Joint forces in the extension of the knee: analysis of a mechanical model. Acta Orthop Scand 57:41-46, 1986

3. Tjepic S, Damur DM, Montavon PM: Biomechanics of the stifle joint. Proceedings of the 1st World Orthopaedic Veterinary Congress, Munich Germany, September 2002, pp 189-190

4. Montavon PM, Damur DM, Tjepic S: Advancement of the tibial tuberosity for the treatment of cranial cruciate deficient canine stifle. Proceedings of the 1st World Orthopaedic Veterinary Congress; Munich Germany, September 2002, p. 152

5. Damur DM: Tibial tuberosity advancement (TTA): Clinical results. Proceedings of the 2005 ACVS Veterinary Symposium. October, 2005, pp 441-442

6. Boudrieau RJ: Tibial tuberosity advancement (TTA): Clinical results. Proceedings of the 2005 ACVS Veterinary Symposium. October, 2005, pp 443-445

7. LAFAYER S, et al: Tibial Tuberosity Advancement for Stabilization of the Canine Cranial Cruciate Ligament-Deficient Stifle Joint: Surgical Technique, Early Results, and Complications in 101 Dogs Veterinary Surgery 36 (6), 573-586.



Call for a no-obligation demonstration!



- Low cost per test
- Small footprint – self-contained reagents
- Simple and fast operation
- 24/7 technical support
- Industry leading accuracy and reproducibility

Clinical Chemistry | Hematology | Monitors | POC Diagnostics | Surgical Power Systems

Now you can keep both your patients and your practice fit and healthy.

Blending an affordable price with unmatched performance characteristics, the Scil Vet ABC hematology analyzer is the ideal solution for any veterinary practice. Over 3,000 animal health care professionals worldwide have made the Scil Vet ABC the diagnostic tool of choice for their laboratories.

Call us today to find out how the Scil Vet ABC will help you run a more profitable practice!

Toll Free: 1-877-724-5838

www.scilvet.com



Quality Performance, Proven Results.

Circle No. 175 on Reader Service Card

Got Something to Say? Is there a topic you'd like to comment on? Send your letters to **MARILYN ITURRI:**
 Editor, Veterinary Practice News
 P.O. Box 6050
 Mission Viejo, CA 92690
 or e-mail at Miturri@BowtieInc.com


News Wanted Send news, press releases and event announcements to Marilyn Iturri:
 Editor, Veterinary Practice News,
 P.O. Box 6050, Mission Viejo, CA 92690,
 or e-mail at Miturri@BowtieInc.com.


VetPracticeNews.com
 Visit us online for daily news updates, an expanded calendar, daily specialty news items, features and more.


www.k-9orthotics.com
Working With Veterinarians To Provide Custom Designed Devices For Your Best Friend
 2616 Beaver Bank Rd
 Beaver Bank, NS
 Canada, B4G 1E6
 Tel: (902) 865-5596 | Fax: (902) 865-5612
info@k-9orthotics.com



Circle No. 201 on Reader Service Card

TRISTAR METALS INC.

PATENTED BATHING TUB W/ ROTATING RAMP

NEW WET PREP LIFT TABLE

NO SQUARE CORNERS
 OVERALL DIMS: 63"L X 24"w X 78"H
 WET SURFACE MEASURES 54"L X 22"W
 FREE-STANDING BASE AVAILABLE
 LIFTS 250 LBS.
 ELECTRIC HYDRAULIC LIFT
RAISES TO 42" LOWERS TO 8"

CALL FOR A FREE CATALOG 877-459-7827
www.tristarvet.com
 e-mail: sales@tristarvet.com

LUXURY SUITES & REPLACEMENT DOORS

Circle No. 186 on Reader Service Card